



Clinical use of optical coherence tomography and fractional flow reserve

Klinička primena optičke koherentne tomografije i frakcione protočne rezerve

Vladimir Ivanović^{*†}, Milovan Petrović^{*†}, Milenko Čanković^{*†},
Anastazija Stojšić-Milosavljević^{*†}, Snežana Čemerlić^{*}

^{*}Institute of Cardiovascular Diseases of Vojvodina, Sremska Kamenica, Serbia;

[†]Faculty of Medicine, University of Novi Sad, Novi Sad, Serbia

Abstract

Introduction. The aim of each diagnostic method is to serve as a guide in deciding about the right patient treatment. During myocardial revascularization the decision to perform revascularization is usually not easy to make, especially in case of borderline stenosis. It has been proven that it is not enough to base morphological evaluation of coronary artery vessel stenosis solely on angiography. It is necessary to include additional modern diagnostic methods for functional analysis and detailed morphological analysis using fractional flow reserve (FFR) and optical coherence tomography (OCT), respectively. **Case reports.** In the first case report we showed the significance of morphological analysis using OCT and proved that it was not lumen stenosis. The second and the third case reports showed the complementarity between functional analysis (FFR) and morphological analysis (OCT) of stenosis in solving a complex coronary disease. The fourth case report showed the significance of OCT in dealing with the recurrent stent restenosis. **Conclusion.** By these short case reports we confirmed that percutaneous coronary intervention (PCI) guided by angiography is definitely not enough in deciding about myocardial revascularization especially in patients with a complex coronary disease. In certain cases FFR and OCT procedures can be complementary methods and improve quality of revascularization, particularly in case of recurrent in-stent restenosis.

Key words:

myocardial revascularization; diagnostic techniques and procedures; tomography, optical coherence; diagnosis, differential; drug-eluting stents; stents.

Apstrakt

Uvod. Cilj svake dijagnostičke metode jeste da bude vodič u donošenju prave odluke za lečenje bolesnika. Prilikom revaskularizacije miokarda donošenje odluke o revaskularizaciji nije uvek lako, posebno u slučaju postojanja graničnih suženja. Dokazano je da morfološka procena stenozе koronarnog krvnog suda nije dovoljna samo na osnovu angiografije, te je neophodna upotreba savremenih dijagnostičkih sredstava za funkcionalnu analizu (npr. procena frakcione protočne rezerve – FFR) i detaljniju morfološku analizu primenom optičke koherentne tomografije (OKT). **Prikazi bolesnika.** U prvom prikazu bolesnika pokazali smo značaj morfološke analize upotrebom OKT na osnovu koga se zaključuje da se ne radi o suženju lumena krvnog suda, u odnosu na samu angiografiju. U drugom i trećem prikazu bolesnika ukazali smo na komplementarnost funkcionalne analize (FFR) i morfološke analize stenozа u rešavanju kompleksne koronarne bolesti, dok smo u četvrtom prikazu ukazali na značaj OKT prilikom rešavanja recidivantnih restenozа stenta. **Zaključak.** Ovom kratkom serijom bolesnika potvrdili smo da angiografski vođena perkutana koronarna intervencija (PCI) svakako nije uvek dovoljna za donošenje odluke o revaskularizaciji krvnog suda, pogotovo kod bolesnika sa kompleksnom koronarnom bolesti. FFR i OKT u pojedinim slučajevima mogu biti komplementarne metode i poboljšati kvalitet revaskularizacije, pogotovo ako se radi o recidivantnim *in-stent* restenozama.

Ključne reči:

miokard, revaskularizacija; dijagnostičke tehnike i procedure; tomografija, optička, koherentna; dijagnoza, diferencijalna; stentovi, lekom obloženi; stentovi.

Introduction

Each diagnostic method serves as a guide in deciding about the right patient treatment. During myocardial revascu-

larization the decision to perform revascularization is usually not easy to make especially in case of borderline stenosis. Accordingly, it has been proven that it is not enough to base morphological evaluation of coronary artery vessel stenosis

solely on angiography. The main disadvantage of coronary angiography in estimation of lesion severity is that it is based on subjective decision grounded on the experience of the interventional cardiologist, and sometimes it is also difficult to present and analyze lesion from several different angles. So, in some cases it is necessary to include additional modern diagnostic methods, thus enabling better morphological evaluation of stenosis as well as the assessment of its hemodynamic significance¹⁻³.

Fractional flow reserve (FFR) is an index of physiological significance for coronary blood vessel stenosis. It is defined as the ratio of a maximal blood flow achievable in the stenotic coronary artery relative to the maximal flow in the same artery if it is normal⁴. According to current guidelines for myocardial revascularization, FFR evaluation is indicated in patients undergoing diagnostic coronary angiography without prior non-invasive functional testing in the presence of borderline lesions and also in patients with multivessel disease (Table 1)⁵.

Case reports

Case one

A 64-year-old male patient was admitted to the Institute of Cardiovascular Diseases of Vojvodina due to angular discomforts, positive stress test and suspected stent restenosis.

Namely, the patient underwent PCI for two DES in the *ramus interventricularis anterior* (RIA) segment in 2010. He was rehospitalized in 2011 when recoronarography was performed and, due to stent restenosis, percutaneous transluminal coronary angioplasty (PTCA) was performed. Coronarography, performed again in 2014, registered previous stents and persistent stenosis immediately behind the second stent.

OCT was performed to assess the stenosis which angiographically appeared as borderline (Figure 1) and to analyze previously deployed stents.

Table 1
Recommendations for the clinical value of intracoronary diagnostic techniques according to the current guidelines for myocardial revascularization

Recommendations	Class	Level
FFR to identify hemodynamically relevant coronary lesion(s) in stable patients when evidence of ischaemia is not available	I	A
FFR-guided PCI in patients with multi-vessel disease	Ila	B
OCT in selected patients to optimize stent implantation	Ilb	C

FFR – fractional flow reserve; OCT – optical coherence tomography; PCI – percutaneous coronary intervention.

The FAME trial pointed out the advantage of FFR when deciding on the percutaneous coronary intervention (PCI) in reference to angiography (FAME I trial) used for drug-eluting stent (DES) implantation in patients with multivessel disease⁶.

Optical coherence tomography (OCT) is a catheter-based invasive imaging system. Using light rather than ultrasound, OCT produces high-resolution *in vivo* images of coronary arteries and deployed stents. OCT is ideally suited to accurate detection of intraluminal structures. Plaque composition, including the presence of lipid pools and intraluminal thrombi, can also be determined. Also, this is the only technique capable of providing accurate measurements of the thickness of the fibrous cap and to detect even minor cap disruptions^{5,7-9}.

Clinical indications and recommendations for OCT usage, except in selected patients to optimize stent implantation, are still not completely defined (Table 1). It still remains unclear when it should be used in clinical practice and whether its use would significantly improve the treatment. However, recent retrospective and observational studies show that clinical outcome can be improved when PCI is performed after OCT^{10,11}.

The use of invasive hemodynamic (FFR) and morphological (OCT) diagnostic procedures in Cath Labs facilitates making the right decision on myocardial revascularization. It also enables assessment whether the optimal result is achieved after the stent implantation.

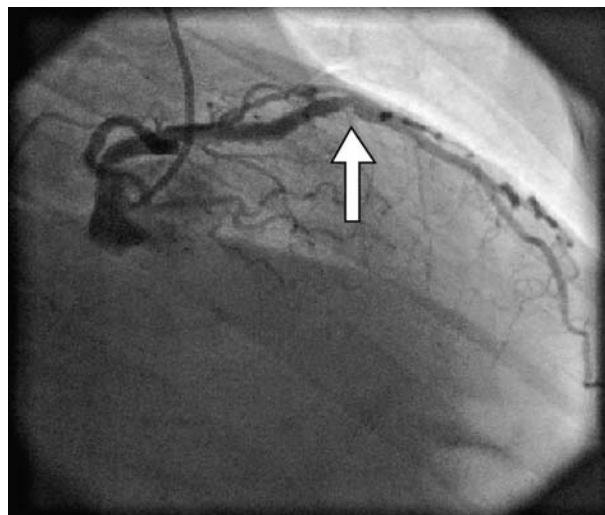


Fig. 1 – Angiography of acute coronary syndrome and suspected stenosis in the area behind the stent.

OCT showed that the deployed stents were well-expanded with a mild restenosis in some segments and with a small aneurysmal dilatation as a part of the artery remodeling after stent implantation (Figure 2). It also showed that it was not lumen stenosis behind the deployed stents, but a curve which probably

made it angiographically appeared as stenosis (Figure 2a). According to OCT finding there were no clear indications for PCI.

Case two

A 53-year-old male patient was admitted to the Institute of Cardiovascular Diseases of Vojvodina in 2014 as an elective for the invasive hemodynamic procedure based on positive stress test. In 2001 this patient underwent PCI with the placement of one bare-metal stent (BMS) at the proximal-medial segment of the RIA. Seven months afterwards the patient underwent recoronarography and PTCA of in-stent restenosis. In 2004 recoronarography was done again registering stent restenosis. It was followed by PTCA which gave optimal results. Due to the front wall non ST-segment elevation myocardial infarction (NSTEMI) the patient was rehospitalized again in 2011. Since it came to coronary disease progression, the patient underwent PCI of one DES distally from the previously deployed BMS. Because of the front wall STEMI induced by the restenosis in the area of BMS, the primary PCI was done in 2012 and DES was placed in RIA.

The final coronarography done in 2014 was presented in this paper. It registered several significant borderline stenoses along the RIA (Figure 3).

FFR analysis was done behind the distal stent giving the result of 0.65, and the repeated FFR analysis above the distal stent gave the result of 0.69. PTCA of proximal stents followed with the drug-eluting balloon (DEB). Control FFR analysis above the distal stent gave the result of 0.84, while FFR analysis below the distal stent resulted in 0.79. Therefore, a DES was implanted in that segment using the overlap technique. The final FFR of the distal area in reference to the deployed stents gave the result of 0.84 (Figure 4).

OCT analysis of the RIA was performed afterwards showing good stent expansion (Figure 5a) and the presence of a stable fibrous plaque with 50% stenosis, proximally from the deployed stents (Figure 5b). Since functional and morphological tests showed insignificant stenosis, it was decided not to perform PCI.

Case three

A 54-year-old male patient was transferred to our institution from the regional hospital for the invasive hemodynamic procedure. The patient was admitted to the regional hospital due to NSTEMI of the inferolateral region which was complicated by ventricular fibrillation. At one point ventricular fibrillation (VF) was stopped with a defibrillator.

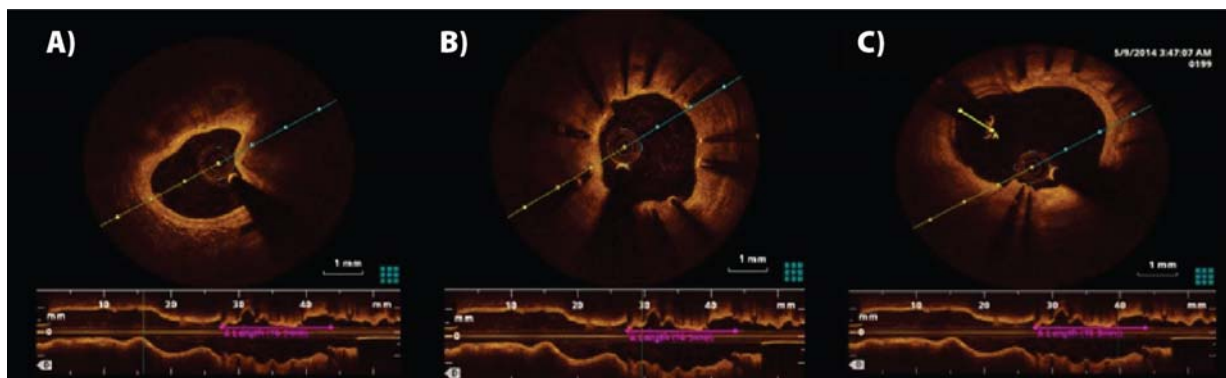


Fig. 2 – A) Optical coherence tomography (OCT) image of stenosis behind the stent; B) OCT image of a well-expanded stent with mild restenosis; C) Aneurysmal dilation of 0.98 mm as part of coronary artery remodeling after stent placement.

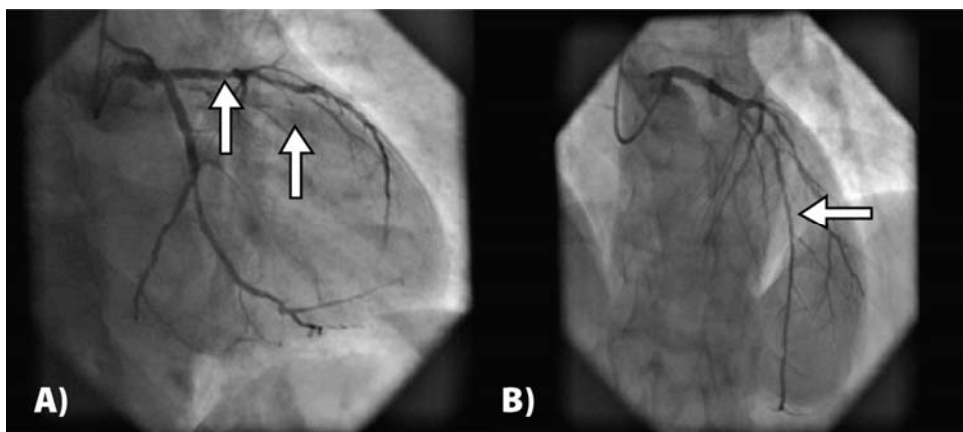


Fig. 3 – A) The first arrow showing stenosis above the previously deployed stents, while the second arrow shows the area of in-stent restenosis; B) The arrow showing persistent stenosis (immediately below the previously deployed stents) in the distal segment of the *ramus interventricularis anterior*.

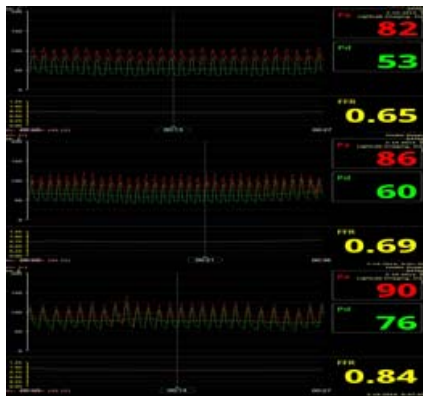


Fig. 4 – The first two and the final fractional flow reserve.

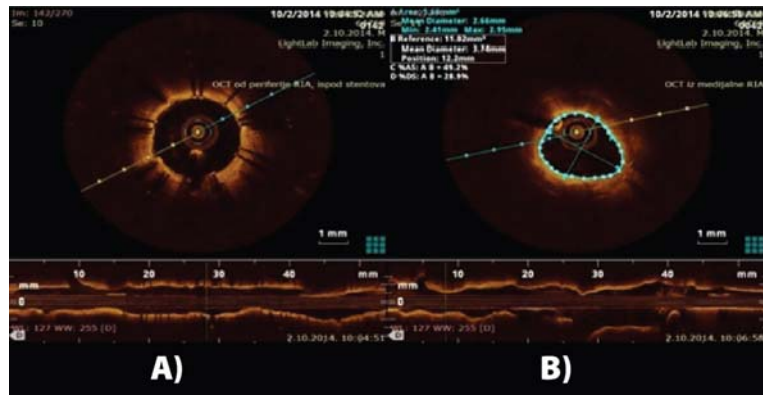


Fig. 5 – A) Optical coherence tomography (OCT) image showing good stent expansion; B) OCT image showing 50% stenosis in the area above the deployed stents.

The patient was transferred to our hospital after his condition was stabilized with medications. Coronarography, performed 18 days after the incident, registered occlusion in the proximal segment of *ramus circumflexus* (RCX) (Figure 6a) and angiographically significant stenosis in the proximal segment of the RIA (Figure 6b). Figure 6c shows RCX after BMS implantation.

FFR on RIA was performed giving the result of 0.90 (Figure 7a).

To thoroughly assess stenosis and the plaque quality thought to be hemodynamically insignificant (angiographically estimated around 85%), OCT was performed. It showed that it

was a stable calcified plaque with 72% stenosis, and lumen cross sectional area (CSA) stenosis of 3.54 mm² (Figure 7b).

Seven days after the intervention the control stress myocardial perfusion scintigraphy (SPECT) was done showing good perfusion in the vascular area of the RIA.

Case four

A 48-year-old male patient was admitted to the hospital as an elective based on positive stress test and suspected stent restenosis. This patient underwent primary PCI in October 2012 due to STEMI of the inferolateral region and two BMS

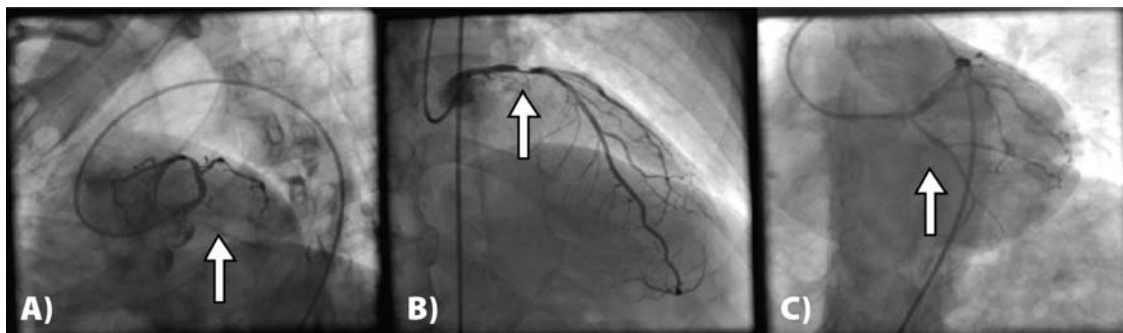


Fig. 6 – A) *Ramus circumflexus* (RCX) occlusion in proximal segment; B) Stenosis of proximal *Ramus interventricularis anterior* (RIA) segment; C) RCX after stent implantation.

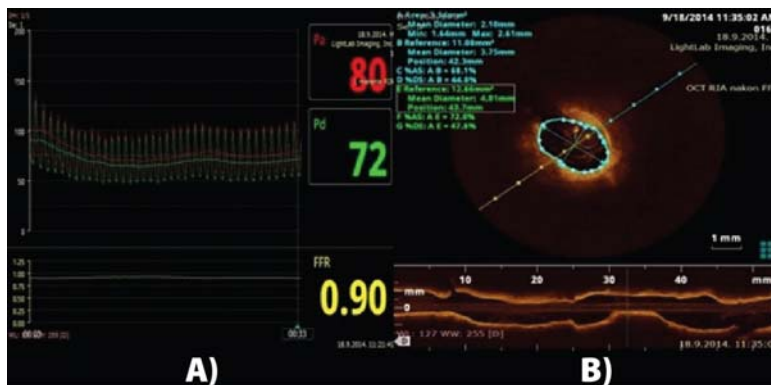


Fig. 7 – A) Fractional flow reserve (FFR) values of the *Ramus interventricularis anterior* (RIA) referential blood vessel diameter; B) Optical coherence tomography (OCT) analysis of the RIA shows 72% stenosis with cross sectional area (CSA) 3.54 mm².

were implanted in the right coronary artery (*arteria coronaria dextra* – ACD). In the second act of the same hospitalization PCI was performed and one BMS was placed in the RIA and one DES in the RCX. The patient was rehospitalized again in 2013 due to anginal discomforts. Recoronarography registered in-stent occlusion in ACD, while the RIA and RCX stents were perviously without any visible significant stenoses. During PCI two DES were implanted in ACD.

The suspicion of stent restenosis led to new recoronarography (6 months after the last PCI procedure) showing no signs of disease progression in the ACS system, while 90% restenosis was registered in the ACD in the proximal and medial segment, i.e. in the area of the previously deployed stents (Figure 8).

Balloon dilatation was performed due to restenosis in the medial segment of ACD while one DES was implanted in the proximal segment of ACD. OCT followed to check the PCI result. It showed that balloon dilatation did not give satisfactory results in certain segments (Figure 9a). Dilatation with a larger-diameter balloon was repeated until the optimal result was achieved (Figure 9b).

Control stress myocardial perfusion scintigraphy was performed 6 months after the last procedure because of the

multiple restenoses in ACD giving a good result. It is our belief that OCT procedure helped us significantly showing that effects of balloon dilatation were not satisfactory. It resulted in repeated dilatation with a larger-diameter balloon until the optimal result was achieved.

Discussion

After coronarography it is not always easy to make decision on blood vessel revascularization. By these short case reports we pointed to the clinical use of FFR and OCT procedures as methods that enable more qualitative treatment of coronary disease in everyday practice.

Invasive functional assessment of stenosis has clearly defined its place in routine PCI procedures as was confirmed by the FAME trial. However, clear indications for the use of OCT in the everyday practice have not yet been established^{6,10}.

OCT is a useful “imaging” method which enables better understanding of vascular biology of atherothrombosis and significantly assists in performing the PCI procedure⁷. Viceconte et al.¹² have shown that OCT can certainly be used when choosing a stent, as well as during stent positioning and expansion.

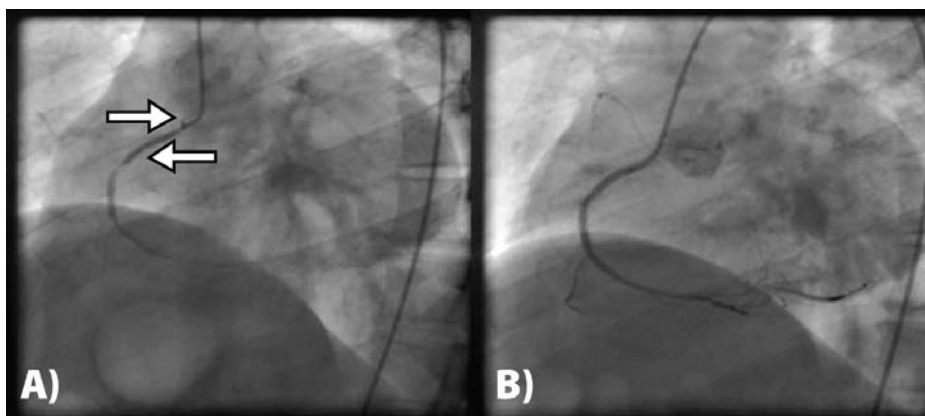


Fig. 8 – A) Arrows showing restenosis in the previously deployed stents; B) Final optimal result after the percutaneous coronary intervention (PCI) procedure deployed stents.

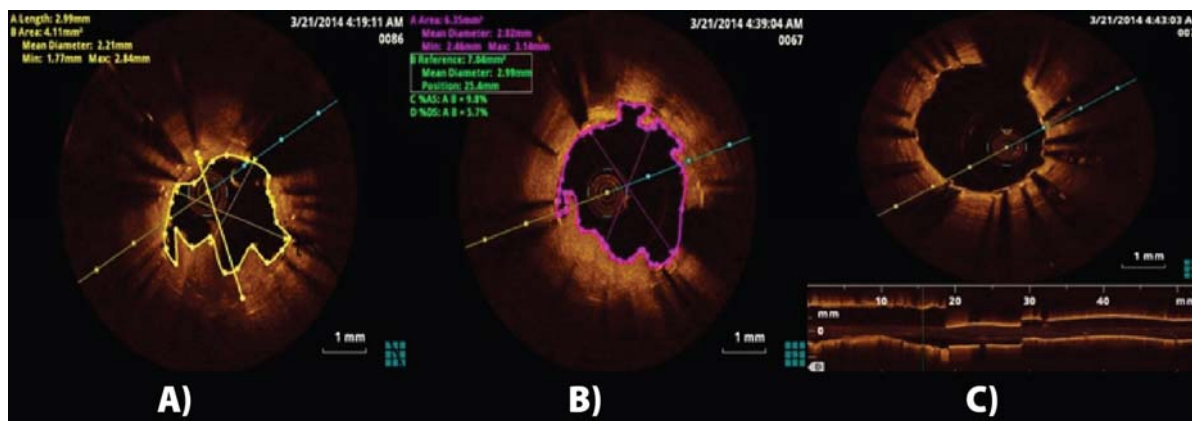


Fig. 9 – A) Image of insufficient postdilatation effect deployed stents, stent cross sectional area (CSA) stenosis 4.11 mm²; B) A satisfactory result after postdilatation using a larger-diameter balloon, stents CSA stenosis 6.35 mm²; C) A well-expanded stent.

Incomplete neointimal coverage after stenting is related to the increased risk of stent thrombosis. In their study Guagliumi et al.¹³ and Finn et al.¹⁴ and have shown that late thrombosis in a DES is related to uncovered stent struts registered by OCT.

A smaller study has shown that availability of morphological and functional data on stenosis received by FFR and OCT is of great significance especially in patients with multiple stenoses because it is impossible to decide what lesion to treat solely on FFR finding. Morphological OCT plaque analysis is significant when there exists suspicion on plaque rupture in the acute phase of coronary syndrome and FFR is not recommended¹⁰.

OCT use proved to be highly significant in detecting a mechanism and severity of in-stent restenosis¹⁵. Secco et al.¹⁶ showed in a study on 14 patients that the use of OCT in in-stent restenosis is of great significance. It enabled the use of larger diameter cutting balloon when the initial smaller diameter cutting balloon failed to give satisfactory results. It further enabled better expansion of a later deployed DES.

Early experiences with OCT-guided implantation of biodegradable vascular scaffolds (BVS) in dealing with complex lesions were promising¹⁷.

We expect that the guidelines for the use of OCT in clinical practice will be more accurately defined when the FORZA study data are obtained¹⁸.

In our study we presented a small series of patients with complex coronary disease in order to show the significance of FFR and OCT use in the routine clinical practice.

In the first case report it we showed that the angiographic finding can largely depend on blood vessel anatomy. Only after the OCT procedure performance it was clear that there were no stenosis but a blood vessel curve. Therefore, there was no need to perform FFR and PCI as was first considered during coronarography.

The third case report showed that it was not enough to base the decision on revascularization solely on angiography, although there had been angiographically registered 85% stenosis estimated by the experience of several interventional cardiologists, cardiac surgeons and computer programs (Radiant Dicom viewer and Microdicom).

After performing FFR we determined that it was not hemodynamically significant stenosis on the RIA, but we were not able to claim with certainty that it was a stable plaque until OCT was performed. After RCX recanalization we decided not to repeat FFR in the RIA because the result of initial measurement was 0.90, if the FFR result was below 0.90 we would have repeated FFR procedure. Based on our more than 10-year experience we do not repeat FFR in such cases. However, to be sure that RIA stenosis is insignificant we used other method as a control, so a week after the PCI procedure the patient underwent control SPECT which showed good perfusion in the vascular area of the RIA.

In the two reported patients there was recurrent stent restenosis. Using OCT we managed to perform satisfying balloon dilatation and stent implantation as well as to check afterwards whether the deployed stents were well-expanded, i.e. to exclude stent malposition. We believe that this precisely plays the crucial role in the prevention of new restenosis after DES implantation.

Conclusion

By these short case reports we confirmed that PCI guided by angiography is definitely not enough to decide on blood vessel revascularization especially in patients with a complex coronary disease.

In certain cases FFR and OCT procedures can be complementary methods and can improve the quality of revascularization, particularly in case of recurrent in-stent restenosis.

REFERENCES

- Muller O, de Bruyne B. Coronary physiology in clinical practice. In: Simon R, Curzen N, Thomas M, editors. Oxford Textbook of Interventional Cardiology. New York: Oxford University Press Inc; 2010. p. 130–46. (English)
- Gonzalo N, Escaned J, Alfonso F, Nolte C, Rodriguez V, Jimenez-Quevedo P, et al. Morphometric Assessment of Coronary Stenosis Relevance With Optical Coherence Tomography. *J Am Coll Cardiol* 2012; 59(12): 1080–9.
- Tobis J, Azarbal B, Slavin L. Assessment of intermediate severity coronary lesions in the catheterization laboratory. *J Am Coll Cardiol* 2007; 49(8): 839–48.
- Pijls NH, de Bruyne B, Peels K, Van DV, Bonnier HJ, Bartunek JJ, et al. Measurement of fractional flow reserve to assess the functional severity of coronary-artery stenoses. *N Engl J Med* 1996; 334(26): 1703–8.
- Windecker S, Kolb P, Alfonso F, Collet J, Cremer J, Falk V, et al. 2014 ESC/EACTS Guidelines on myocardial revascularization: The Task Force on Myocardial Revascularization of the European Society of Cardiology (ESC) and the European Association for Cardio-Thoracic Surgery (EACTS) Developed with the special contribut. *Eur Heart J* 2014; 35(37): 2541–619.
- Tonino PA, de Bruyne B, Pijls NH, Siebert U, Ikeno F, van't Veer M, et al. Fractional flow reserve versus angiography for guiding percutaneous coronary intervention. *N Engl J Med* 2009; 360(3): 213–24.
- Bezerra HG, Costa MA, Guagliumi G, Rollins AM, Simon DI. Intracoronary Optical Coherence Tomography: A Comprehensive Review. *JACC Cardiovasc Interv* 2009; 2(11): 1035–46.
- Tearney GJ, Regar E, Akasaka T, Adriaenssens T, Barlis P, Bezerra HG, et al. International Working Group for Intravascular Optical Coherence T. Consensus standards for acquisition, measurement, and reporting of intravascular optical coherence tomography studies: a report from the International Working Group for Intravascular. *J Am Coll Cardiol* 2012; 59(12): 1058–72.
- Cassar A, Matsuo Y, Herrmann J, Li J, Lennon RJ, Gulati R, et al. Coronary atherosclerosis with vulnerable plaque and complicated lesions in transplant recipients: new insight into cardiac allograft vasculopathy by optical coherence tomography. *Eur Heart J* 2013; 34(33): 2610–7.
- Stefano GT, Bezerra HG, Attizzani G, Chamié D, Mehanna E, Yamamoto H, et al. Utilization of frequency domain optical coherence tomography and fractional flow reserve to assess inter-

- mediate coronary artery stenoses: conciliating anatomic and physiologic information. *Int J Cardiovasc Imag* 2011; 27(2): 299–308.
11. Prati F, Di VL, Biondi-Zoccai G, Occhipinti M, La MA, Tamburino C, et al. Angiography alone versus angiography plus optical coherence tomography to guide decision-making during percutaneous coronary intervention: the Centro per la Lotta contro l'Infarto-Optimisation of Percutaneous Coronary Intervention (CLI-OPCI) study. *EuroIntervention* 2012; 8(7): 823–9.
 12. Viceconte N, Chan PH, Barrero EA, Ghilencea L, Lindsay A, Foin N, et al. Frequency domain optical coherence tomography for guidance of coronary stenting. *Int J Cardiol* 2013; 166(3): 722–8.
 13. Guagliumi G, Sirbu V, Musumeci G, Gerber R, Biondi-Zoccai G, Ikejima H, et al. Examination of the In Vivo Mechanisms of Late Drug-Eluting Stent Thrombosis. *JACC Cardiovasc Interv* 2012; 5(1): 12–20.
 14. Finn AV, Joner M, Nakazawa G, Kolodgie F, Newell J, John MC, et al. Pathological correlates of late drug-eluting stent thrombosis: strut coverage as a marker of endothelialization. *Circulation* 2007; 115(18): 2435–41.
 15. di Mario C, Barlis P. Optical coherence tomography: a new tool to detect tissue coverage in drug-eluting stents. *JACC Cardiovasc Interv* 2008; 1(2): 174–5.
 16. Secco GG, Foin N, Viceconte N, Borgia F, de Luca G, di Mario C. Optical coherence tomography for guidance of treatment of in-stent restenosis with cutting balloons. *EuroIntervention* 2011; 7(7): 828–34.
 17. Mattesini A, Secco GG, Dall'Ara G, Ghione M, Rama-Merchan JC, Lupi A, et al. ABSORB Biodegradable Stents Versus Second-Generation Metal Stents. *JACC Cardiovasc Interv* 2014; 7(7): 741–50.
 18. Burzotta F, Leone A, de Maria G, Niccoli G, Coluccia V, Pirozzolo G, et al. Fractional flow reserve or optical coherence tomography guidance to revascularize intermediate coronary stenosis using angioplasty (FORZA) trial: study protocol for a randomized controlled trial. *Trials* 2014; 15(1): 140.

Received on April 24, 2015.

Accepted on May 4, 2015.

Online First March, 2016.